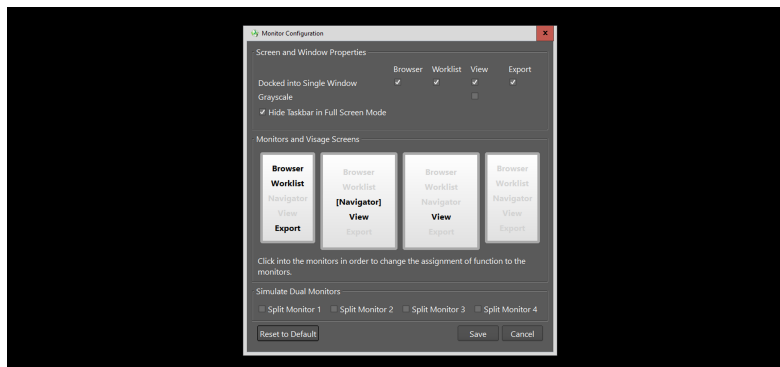


Setting-up monitor configuration with report view section in Visage

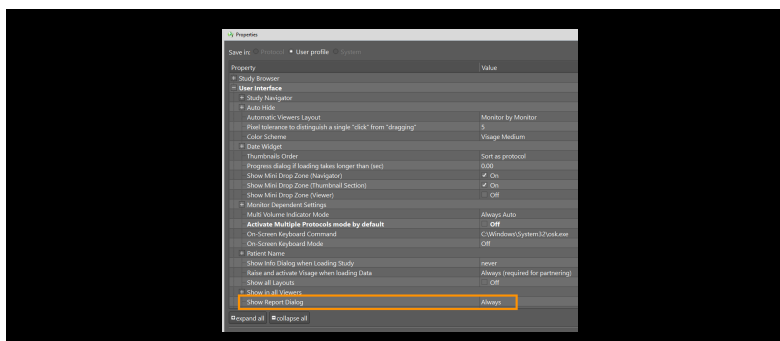
Mohanad Alhumayed (R3)



1

Monitor configuration:

File > Preferences > Monitor Configuration > select the configuration and settings as shown above > Save



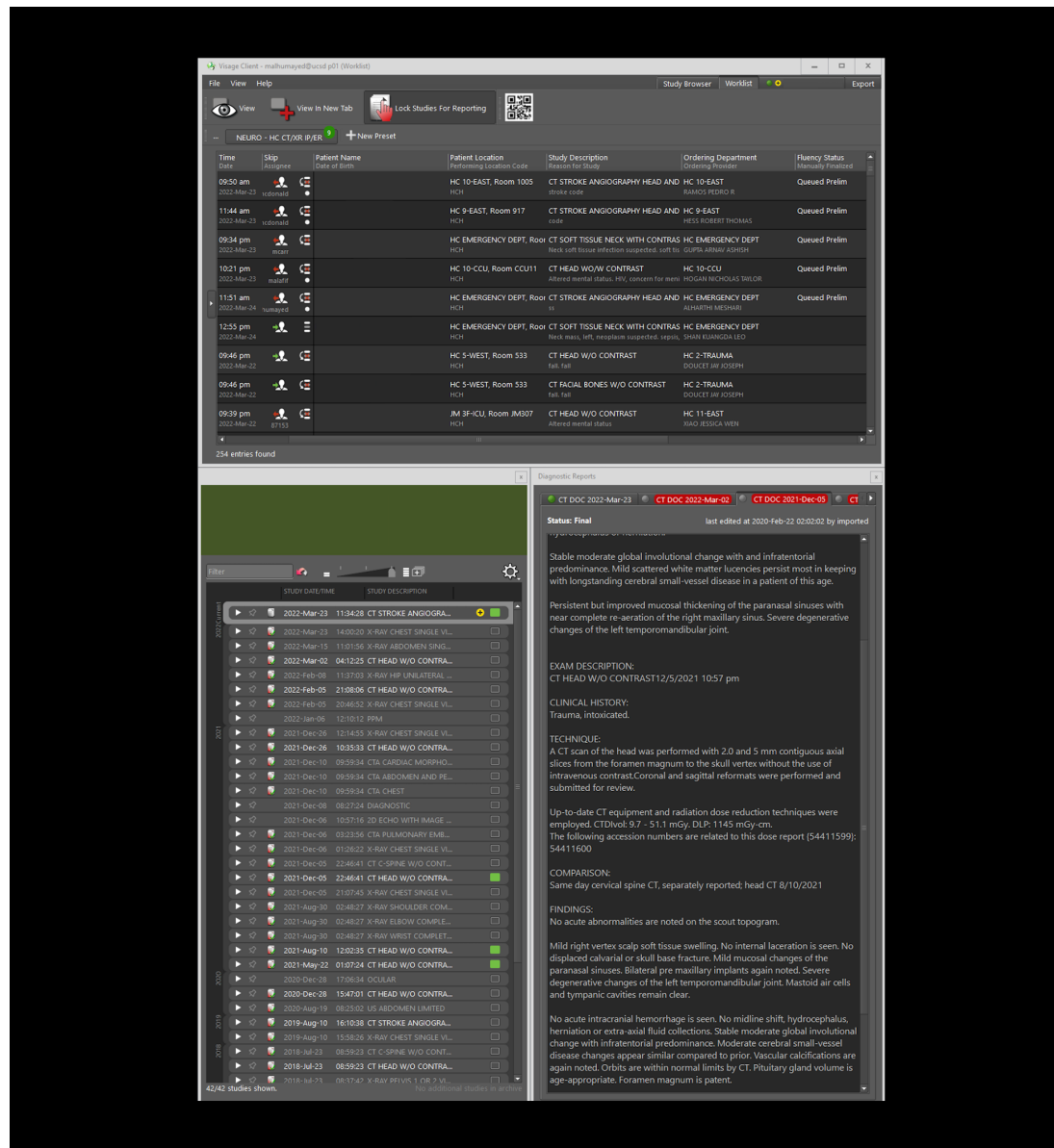
2

Display prior reports when viewing a study:

File > Preferences > Properties > User Interface > Show in all Views > Show Report Dialog > Always > Save

3

Open a new study > Manually arrange the windows in the preferred layout (monitor configuration will be saved in the user's profile for future sessions)



IMPAX 6.7.0.6011 "Site"

Available Malhumayed Help Logout

Study Highlights

Reason for Study: trauma intoxicated

Requesting Physician: HOLDAWAY, JESSICA

Requesting Department:

Technologist: RD

Institution: UCSD Hillcrest | ID DEPARTMENT

Patient Name:

Other Patient Names:

Patient Comments:

Study List

Radiology (39) Teaching Files

Current Studies (1)

Study List (38/38)

Filter studies

Stu...	Study Description	Reason for Study	Study...	Study Ti...
App...	X-RAY CHEST S...		3/23/2022	2:00 PM
New	CT STROKE AN...		3/23/2022	11:34 AM
App...	X-RAY ABDO...	eval stool burd...	3/15/2022	11:01 AM
App...	CT HEAD W/O...	Dizziness;CALL...	3/2/2022	4:12 AM
App...	X-RAY HIP UNI...	Hip pain	2/8/2022	11:37 AM
App...	CT HEAD W/O...	Altered mental...	2/5/2022	9:08 PM
App...	X-RAY CHEST S...	AMS	2/5/2022	8:46 PM
App...	X-RAY CHEST S...	hypoxia covid	12/26/2021	12:14 PM
App...	CT HEAD W/O...	Syncope	12/26/2021	10:35 AM
App...	CTA CHEST	TAVR evaluation	12/10/2021	9:59 AM
App...	CTA ABDOMEN...	TAVR evaluation	12/10/2021	9:59 AM
App...	CTA CARDIAC...	TAVR evaluation	12/10/2021	9:59 AM
App...	CTA PULMONA...	Clinical gestalt...	12/6/2021	3:23 AM
App...	X-RAY CHEST S...	post IJ insertion	12/6/2021	1:26 AM
App...	CT HEAD W/O...	trauma intoxica...	12/5/2021	10:46 PM
App...	CT C-SPINE W/...	trauma intoxica...	12/5/2021	10:46 PM
App...	X-RAY CHEST S...	Infectious workup	12/5/2021	9:07 PM
App...	X-RAY WRIST C...	wrist pain	8/30/2021	2:48 AM
App...	X-RAY ELBOW...	arm pain	8/30/2021	2:48 AM
App...	X-RAY SHOULD...	Fall	8/30/2021	2:48 AM
App...	CT HEAD W/O...	Head trauma	8/10/2021	12:02 PM
App...	CT HEAD W/O...	Altered mental...	5/22/2021	1:07 AM
App...	OCCULAR		12/28/2020	5:06 PM
App...	CT HEAD W/O...	Vision changes	12/28/2020	3:47 PM
App...	US ABDOMEN L...	RUQ and GB	8/19/2020	8:25 AM
App...	CT STROKE AN...	Indications:>...	8/10/2019	4:10 PM
App...	CT C-SPINE W/...	Indications:>...	8/10/2019	3:58 PM
App...	CT HEAD W/O...	Indications:>tr...	7/23/2018	8:59 AM
App...	CT C-SPINE W/...	Clinical History...	7/23/2018	8:59 AM
App...	X-RAY PELVIS...	Indications:>tr...	7/23/2018	8:37 AM
App...	X-RAY CHEST S...	Chest Views:>...	7/23/2018	8:36 AM
App...	US ABDOMEN L...	Defer to Ultras...	7/23/2018	8:35 AM
App...	X-RAY CHEST F...	Indications:>...	3/5/2018	12:30 AM
App...	MRI BRAIN WO...	Clinical History...	1/28/2015	7:42 AM
App...	CHEST SINGLE...	Clinical History...	12/8/2014	3:08 PM
App...	CHEST 2 VIEW...	Clinical History...	10/21/2014	9:56 PM

Order: Placed on Unknown Date

Study Approved

Description

Patient ID:

Patient Name:

Patient Birth Date:

Patient Sex:

Current Location:

Requested Procedure: 70450

DATE: 12/5/2021 10:46 PM

Study Description:

CT HEAD W/O CONTRAST

Report Approved by MARIN MCDONALD 12/6/2021 9:35 AM

Report Study Comments (1)

The following accession numbers are related to this dose report

54411599;

54411600

COMPARISON:

Same day cervical spine CT, separately reported; head CT 8/10/2021

FINDINGS:

No acute abnormalities are noted on the scout topogram.

Mild right vertex scalp soft tissue swelling. No internal laceration is seen. No displaced calvarial or skull base fracture. Mild mucosal changes of the paranasal sinuses. Bilateral pre maxillary implants again noted. Severe degenerative changes of the left temporomandibular joint. Mastoid air cells and tympanic cavities remain clear.

No acute intracranial hemorrhage is seen. No midline shift, hydrocephalus, herniation or extra-axial fluid collections. Stable moderate global involutional change with infratentorial predominance. Moderate cerebral small-vessel disease changes appear similar compared to prior. Vascular calcifications are again noted. Orbits are within normal limits by CT. Pituitary gland volume is age-appropriate. Foramen magnum is patent.

CONCURRENT SUPERVISION:

I have reviewed the images and agree with the Resident's interpretation.

Signed by: Mcdonald, Marin 12/06/2021 08:35:15

IMPRESSION:

Right vertex scalp soft tissue swelling without displaced calvarial fracture seen. No acute intracranial hemorrhage, mass effect, midline shift, hydrocephalus or herniation.

Stable moderate global involutional change with and infratentorial predominance. Mild scattered white matter lucencies persist most in keeping with longstanding cerebral small-vessel disease in a patient of this age.

Persistent but improved mucosal thickening of the paranasal

View Client - malhumayed@ucsd.edu (Worklist)

File View Help

Study Browser Worklist Export

View View In New Tab Lock Studies for Reporting

NEURO - HC CT/XR IP/ER + New Preset

Time Date	Skip Assignee	Patient Name Date of Birth	Patient Location Performing Location Code	Study Description Reason for Study	Ordering Department Ordering Provider	Fluency Status
09:50 am 2022-Mar-23	icdonald	Patient name MRN	(FIV, F) HCH	CT HEAD W/O CONTRAST	HC 11-EAST	Queued Prelim
11:44 am 2022-Mar-23	icdonald	(FIV, F) HCH	HC 9-EAST, Room 917	CT STROKE ANGIOGRAPHY HEAD AND	HC 9-EAST	Queued Prelim
09:34 pm 2022-Mar-23	icdonald	(FIV, F) HCH	HC EMERGENCY DEPT, Room 100	CT SOFT TISSUE NECK WITH CONTRAS	HC EMERGENCY DEPT	Queued Prelim
10:21 pm 2022-Mar-23	malaff	(SIV, M) HCH	HC 10-CCU, Room CCU11	CT HEAD W/O CONTRAST	HC 10-CCU	Queued Prelim
11:51 am 2022-Mar-24	turneyd	(SIV, F) HCH	HC EMERGENCY DEPT, Room 100	CT STROKE ANGIOGRAPHY HEAD AND	HC EMERGENCY DEPT	Queued Prelim
12:55 pm 2022-Mar-24	turneyd	(SIV, F) HCH	HC EMERGENCY DEPT, Room 100	CT SOFT TISSUE NECK WITH CONTRAS	HC EMERGENCY DEPT	Queued Prelim
09:46 pm 2022-Mar-27	turneyd	(SIV, F) HCH	HC 10-CCU, Room CCU11	CT HEAD W/O CONTRAST	HC 10-CCU	Queued Prelim
09:46 pm 2022-Mar-27	turneyd	(SIV, F) HCH	HC 10-CCU, Room CCU11	CT HEAD W/O CONTRAST	HC 10-CCU	Queued Prelim
09:39 pm 2022-Mar-22	turneyd	(SIV, F) HCH	HC 10-CCU, Room CCU11	CT HEAD W/O CONTRAST	HC 10-CCU	Queued Prelim

254 entries found

Diagnostic Reports

CT DOC 2022-Mar-23 CT DOC 2022-Mar-02 CT DOC 2021-Dec-05 CT

Status: Final last edited at 2020-Feb-22 02:02:02 by imported

Stable moderate global involutional change with and infratentorial predominance. Mild scattered white matter lucencies persist most in keeping with longstanding cerebral small-vessel disease in a patient of this age.

Persistent but improved mucosal thickening of the paranasal sinuses with near complete re-aeration of the right maxillary sinus. Severe degenerative changes of the left temporomandibular joint.

EXAM DESCRIPTION:

CT HEAD W/O CONTRAST 12/5/2021 10:57 pm

CLINICAL HISTORY:

Trauma, intoxicated.

TECHNIQUE:

A CT scan of the head was performed with 2.0 and 5 mm contiguous axial slices from the foramen magnum to the skull vertex without the use of intravenous contrast. Coronal and sagittal reformats were performed and submitted for review.

Up-to-date CT equipment and radiation dose reduction techniques were employed. CTDIvol: 9.7 - 51.1 mGy. DLP: 1145 mGy-cm. The following accession numbers are related to this dose report (54411599): 54411600

COMPARISON:

Same day cervical spine CT, separately reported; head CT 8/10/2021

FINDINGS:

No acute abnormalities are noted on the scout topogram.

Mild right vertex scalp soft tissue swelling. No internal laceration is seen. No displaced calvarial or skull base fracture. Mild mucosal changes of the paranasal sinuses. Bilateral pre maxillary implants again noted. Severe degenerative changes of the left temporomandibular joint. Mastoid air cells and tympanic cavities remain clear.